

# *Tritrichomonas foetus*: A New Agent of Feline Diarrhea

» Mary Katherine Tolbert,  
DVM

» Jody L. Gookin, DVM,  
PhD, DACVIM

North Carolina State  
University

**Abstract:** *Tritrichomonas foetus* is a single-celled, flagellated protozoal parasite that colonizes the feline colon and distal ileum. Infected cats may be asymptomatic or may have clinical signs that include malodorous large bowel diarrhea. *T. foetus* infection is common in, but not limited to, high-density populations of young, purebred cats. Testing for this parasite is still not routine at most veterinary clinics, and *T. foetus* is often misdiagnosed as *Giardia* spp. *T. foetus*-specific tests (fecal culture and polymerase chain reaction) should be considered in cats with large bowel diarrhea, especially those in which traditional diagnostics and treatments for other causes of feline large bowel diarrhea have failed to reach a clinical resolution. Recognition of this newly emerging disease and appropriate sample handling are critical for the detection and treatment of feline trichomoniasis.

## At a Glance

► Clinical Presentation  
Page 374

► Clues to Identifying  
*Tritrichomonas foetus*  
Infection in Cats  
Page 375

► Diagnostic Approach to  
*Tritrichomonas foetus*  
Infection  
Page 375

► Diagnosis  
Page 375

► Therapy  
Page 378

► Tips for Avoiding  
Ronidazole Toxicosis  
Page 380

**T**richomonads are protozoan parasites characterized by an undulating membrane that extends along the length of their pear-shaped body and anterior flagella that vary in number depending on the species (**FIGURE 1**). These single-celled organisms are obligate parasites of warm, moist, anaerobic environments within the gastrointestinal or genitourinary tract of a variety of host species. They are often considered to be nonpathogenic commensals; however, several pathogenic species exist.

*Tritrichomonas foetus* is well recognized as a venereal pathogen of cattle. Recently, it was discovered to be a pathogen of cats, in which the parasites colonize the distal ileum and colon, resulting in chronic large bowel diarrhea.<sup>1-3</sup> The prevalence of infection can be quite high, particularly in young cats housed in high-density populations (e.g., shelters, breeding facilities)<sup>4</sup>; older and mixed-breed cats have also been identified with a high

prevalence of infection.<sup>5,6</sup> *T. foetus* has been found in many countries.<sup>4,5,7-9</sup> The reported prevalence of *T. foetus* in cats is 10% in the United Kingdom and 31% in the United States.<sup>4,6-8</sup> No breed of cat is known to be immune to *T. foetus*.

Unlike *Giardia* spp, trichomonads do not form cysts and therefore cannot survive for prolonged periods in the environment. They can survive for up to 3 days in moist feces.<sup>10</sup> Trichomonads are presumably transmitted from cat to cat via shared litterboxes, where the parasites can be transferred from the feces of one cat to the paws of another. The parasites are subsequently ingested during grooming. There is little evidence at this time for venereal transmission of *T. foetus* in cats.<sup>11</sup>

## Clinical Presentation

The most characteristic clinical sign of *T. foetus* infection is chronic waxing and waning large bowel diarrhea (**BOX 1**). The diarrhea frequently has the consistency

## BOX 1

### Clues to Identifying *Tritrichomonas foetus* Infection in Cats

- ▶ Young cat obtained from a cattery or shelter
- ▶ Chronic waxing and waning, malodorous, large bowel diarrhea
- ▶ Normal appetite with no loss of body condition
- ▶ Diarrhea responds to antibiotics but recurs when drugs are discontinued
- ▶ Trophozoites observed in feces are unresponsive to treatment for *Giardia* spp

of cow feces and is malodorous; it occasionally contains mucus or fresh blood (FIGURE 2). Severely affected cats may have involuntary fecal dribbling and inflammation of the anus. Because the infection is predominantly restricted to the large intestine, cats maintain a normal appetite and do not have muscle wasting.<sup>1,5</sup> In many cats, the diarrhea improves in response to antibiotic therapy, only to return when the antibiotics are discontinued. Importantly, many infected cats do not show any clinical signs, particularly older cats. Therefore, all cats in contact with a cat diagnosed with *T. foetus* or housed in a high-risk environment may be asymptomatic carriers of the infection.

### Diagnosis

*T. foetus* infection is diagnosed on the basis of identification of the organism on a fecal smear, after culture of feces in media fostering the growth of *T. foetus*, or by polymerase chain reaction (PCR) testing performed on DNA extracted from a fecal sample (BOX 2). *T. foetus* cannot be detected by routine fecal analyses such as centrifugation flotation, and the organisms do not survive refrigeration. Suitable fecal samples may be obtained by (1) collecting a freshly voided specimen devoid of contaminating litter, (2) inserting a fecal loop per rectum into the proximal colon, or (3) passing a red rubber catheter into the proximal colon for the instillation and recovery of several milliliters of sterile saline. We prefer the saline flush technique, in which approximately 10 mL of sterile saline is injected through the catheter into the colon and then gently aspi-

## BOX 2

### Diagnostic Approach to *Tritrichomonas foetus* Infection

#### Fecal sample collection

- ▶ Collect feces immediately after voiding or directly from the colon using a fecal loop or saline flush technique
- ▶ Do not refrigerate the sample
- ▶ Use the quantity of feces that is appropriate for the test being conducted
- ▶ Ensure that the cat has not received antibiotics within the past 7 days

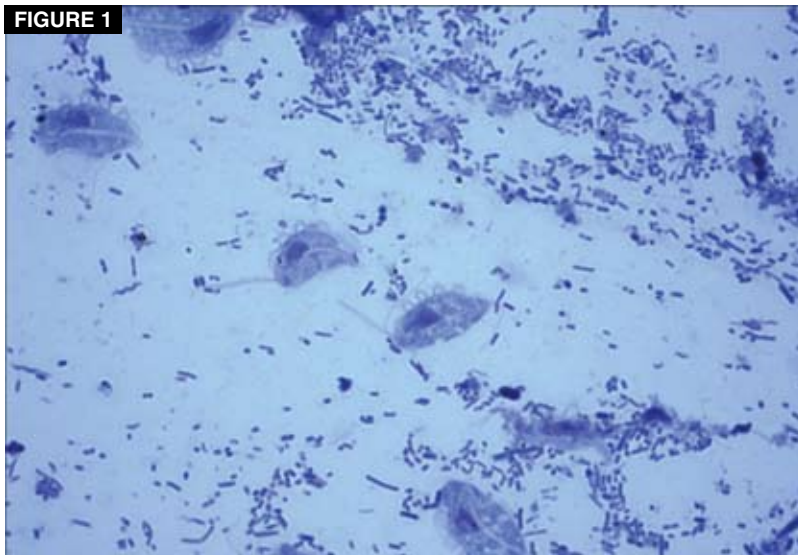
#### Testing methods

- ▶ Examination of a direct fecal smear (wet mount) for trichomonads (carefully distinguish *T. foetus* from *Giardia* spp trophozoites)
- ▶ Examination of fecal culture (InPouch TF media) for trichomonads
- ▶ Polymerase chain reaction for *T. foetus* using DNA extracted from feces (most sensitive)

rated (FIGURE 3). A drop of the recovered solution can then be examined directly under the microscope for trichomonads or placed in a fecal culture pouch. Alternatively, the solution can be sedimented in a centrifuge and submitted for PCR analysis.

Fecal samples should always be fresh, free

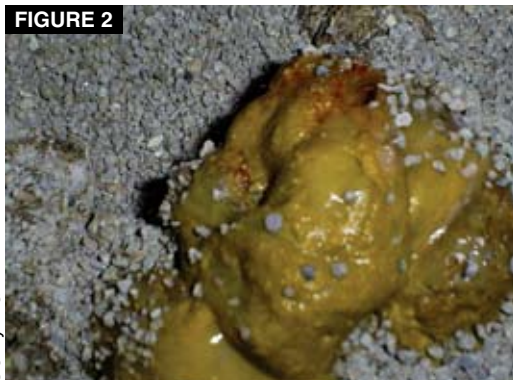FIGURE 1



***Tritrichomonas foetus* in a fecal smear prepared from a cat with diarrhea. Note the undulating membrane and anterior flagella of each organism. (Diff-Quik; magnification: 400×)**

© Jody L. Gookin, DVM, PhD, DACVIM

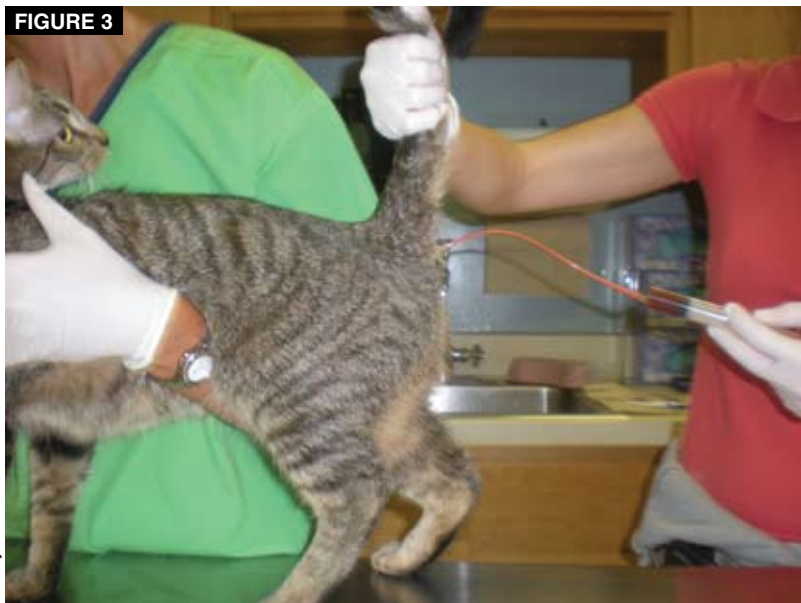FIGURE 2



© Jody L. Gookin

**Typical appearance of a bowel movement from a cat with *T. foetus* infection. The feces are poorly formed, have the consistency of cow feces, and may contain mucus or fresh blood.**

FIGURE 3



© Jody L. Gookin

**To obtain a flush specimen of the colon, insert a red rubber catheter through the anus of the cat into the proximal colon and instill and aspirate approximately 10 mL of sterile saline. A drop of the resulting solution can be applied to a microscope slide, coverslipped, and examined with a light microscope for the presence of motile trichomonads. A video of this procedure may be viewed at [JodyGookin.com](http://JodyGookin.com).**

of contaminating litter, and kept unrefrigerated before testing. If a stool sample is being transported to the veterinary clinic, advise the owner to keep it warm and moist. Samples obtained from nondiarrheic or dry stools are unsuitable for use in testing for *T. foetus* and rarely test positive even if infection is present. Further, concurrent administration of antibiotics at the time the sample is collected appears to decrease the success of finding *T. foetus*. Therefore, administration of antibiotics should be stopped for several days before testing.

No available diagnostic tests have 100% sensitivity for detection of the infection. If test results are positive, the cat is considered to be infected with *T. foetus*. However, if test results are negative, the possibility of infection cannot be excluded, particularly in cases with a high index of suspicion for infection. In these cases, veterinarians should consider repeated testing.

### Direct Fecal Smear


The fecal smear is the cheapest and simplest option for diagnosis of *T. foetus* infection; however, it is also the least sensitive. For direct fecal smears, fresh feces are diluted in saline, and a drop of the solution is examined under a coverslip using a light microscope (FIGURE 4). Trichomonads are nearly identical in size to *Giardia* spp trophozoites and must be carefully distinguished. The keys to distinguishing trichomonads from *Giardia* spp are (1) the presence of an undulating membrane on trichomonads and (2) the characteristic “falling-leaf” motility of *Giardia* spp, which contrasts with the rigorously forward motion of trichomonads. Videomicroscopy images to aid in the differentiation of trichomonads from *Giardia* spp are available online ([JodyGookin.com](http://JodyGookin.com)).

It is important to remember that trichomonads do not form cysts. If difficulty is encountered in distinguishing trichomonads from *Giardia* spp, we recommend performing a *Giardia* ELISA on the feces, as *T. foetus* does not test positive with this assay. However, coinfection of cats with *Giardia* spp and *T. foetus* is common.<sup>4</sup>

### Fecal Culture

Fecal culture for *T. foetus* is also relatively inexpensive; however, it has greater sensitivity than direct fecal smear for detection of infection. Cultures can be performed using a commercial culture test kit (InPouch TF-Feline, Biomed Diagnostics, White City, OR). The culture pouches are made of clear plastic and contain a proprietary medium as well as antibiotics that suppress unwanted bacterial growth. The pouch is inoculated with a fecal sample the size of a grain of rice and is then incubated (FIGURE 5). If too much feces is inoculated into the pouch, fecal bacteria will overgrow and the test will be nondiagnostic. The pouch can be incubated at either 98.6°F (37°C)

FIGURE 4



© Jody L. Gookin

**A direct fecal smear preparation after application of a coverslip. Note that very little feces is used to prepare the smear. If smears are prepared with too much feces, motility of the organisms is impaired, making them more difficult to identify under the microscope.**

### QuickNotes

**Cats with large bowel diarrhea, especially those in high-density populations, should be tested for *T. foetus* infection using fecal smears, agent-specific culture media, or polymerase chain reaction testing.**

or room temperature. At 98.6°F, trichomonads multiply quickly, and many organisms can be observed by light microscopy within 72 hours. If the pouch is incubated at room temperature, fewer trichomonads will be present, and it may take as many as 12 days after inoculation to obtain results.<sup>12</sup> Motile trichomonads can be observed in the pouch by placing the intact pouch on the stage of a light microscope. The examiner need not have expertise in organism identification because the pouch test does not support the growth of similar-appearing organisms such as *Giardia* spp. The fecal sample must contain live organisms to obtain positive results from fecal culture, and optimum growth conditions for the organisms must be maintained during the test period. Therefore, care must be used in handling the specimen and the pouch to avoid a false-negative result. We strongly recommend that these cultures be performed in the clinic rather than by an external diagnostic laboratory so that the trichomonads do not die during shipment of the pouch.

### Polymerase Chain Reaction Testing

Trace amounts of *T. foetus* DNA in the feces can be identified using a commercial PCR assay. Although this test is the most expensive option for *T. foetus* detection, it provides superior sensitivity (as few as 10 *T. foetus* organ-

isms per 100-mg fecal sample) and specificity and can detect living and dead organisms.<sup>13,14</sup> Several commercial facilities for testing exist. Our laboratory's guidelines for submission of fecal samples for PCR analysis are that approximately 100 mg of feces (about the size of a lima bean) should be placed into a red-top Vacutainer tube filled with 3 to 5 mL of 70% isopropyl alcohol (rubbing alcohol) and shipped at room temperature.<sup>4</sup>

### Therapy

Historically, antiprotozoal therapies for *T. foetus*, including metronidazole, were ineffective in eradicating the parasites and often resulted in prolongation of clinical signs.<sup>10</sup> Recently, ronidazole, a nitroimidazole similar to metronidazole, was shown to have in vitro and in vivo activity against *T. foetus*.<sup>15,16</sup> Ronidazole is not approved by the US Food and Drug Administration for use in companion animals and is currently banned for use in food animals because of potential human hazards. Accordingly, due diligence is required to protect people from exposure to ronidazole (such as wearing gloves when handling the medication), and veterinarians are advised to prescribe the drug only in cases of confirmed *T. foetus* infection after obtaining the owner's informed consent.

Recent studies investigating the pharmacokinetics of ronidazole in cats suggest that 30 mg/kg PO q24h for 14 days is likely to be most effective in resolving diarrhea and eradicating *T. foetus* infection in cats.<sup>17</sup> There is no evidence that higher doses of ronidazole or administration for a longer period of time is more effective. The drug is rapidly and completely absorbed by the gastrointestinal tract and has a long elimination half-life. These properties appear to predispose some cats to neurotoxicosis while receiving the drug.<sup>16,18</sup> Signs of ronidazole neurotoxicosis include lethargy, inappetence, ataxia, and seizures.<sup>18</sup> If the drug is withdrawn immediately, these generally resolve, but they may continue to worsen for the next few days before slowly subsiding and may require costly and intensive emergency veterinary care.<sup>18</sup> Accordingly, cats

<sup>4</sup>Submission forms and instructions for submitting fecal samples to the North Carolina State University College of Veterinary Medicine for *T. foetus* PCR testing are available at [JodyGookin.com](http://JodyGookin.com).

## BOX 3

### Tips for Avoiding Ronidazole Toxicosis

- ▶ Calculate the dose based on a current, accurate body weight.
- ▶ Do not exceed 30 mg/kg PO q24h for 14 days.
- ▶ Monitor cats closely. Stop treatment if clinical signs of lethargy, inappetence, or neurologic disease are observed.
- ▶ Do not reinstitute or repeat treatment with ronidazole if signs of toxicosis have occurred.

must be monitored closely while receiving ronidazole. Signs

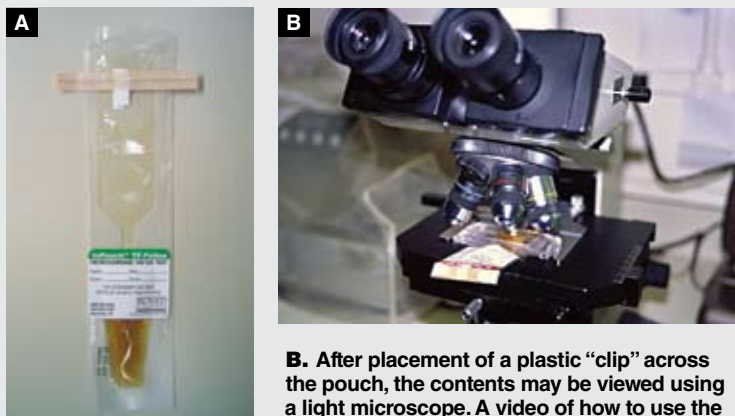
of neurotoxicosis may be easier to observe if the treated cat is engaged each day in a playful activity (e.g., chasing a laser pointer) that requires coordination and agility. If signs of toxicosis are observed, owners should be advised to resist the temptation to continue or complete treatment with ronidazole. Continuing treatment after signs of toxicosis are observed could result in life-threatening complications. **BOX 3** gives some tips for avoiding ronidazole toxicosis. If treatment must be discontinued because of neurotoxicosis, we recommend that the cat be retested for *T. foetus* infection. Many of these cats have received sufficient ronidazole to have cleared the infection.

Most cats with *T. foetus* infection show significant improvement to resolution of diarrhea during the course of ronidazole treatment. *T. foetus* can cause considerable inflammation in the colon, and it often takes several weeks for diarrhea to completely resolve after the organisms are eradicated. If diarrhea persists for more than 14 days after treatment, the cat should be retested for *T. foetus*. If test results are negative for *T. foetus*, veterinarians should consider other causes of diarrhea, such as concurrent infection or dietary intolerance.

Reasons for failure of ronidazole to eradicate *T. foetus* infection include insufficient dose or duration of therapy, administration of impotent formulations of the drug (e.g., 10% powder formulation for pigeons), failure of the cat to consume the drug (e.g., spat out liq-

## FIGURE 5

The InPouch TF culture system for the diagnosis of feline *T. foetus* infection.



A. A pouch with sample.

B. After placement of a plastic “clip” across the pouch, the contents may be viewed using a light microscope. A video of how to use the pouch for cultivation of *T. foetus* from feline feces may be viewed at [JodyGookin.com](http://JodyGookin.com).

© Jody L. Gookin

uid), or reinfection with *T. foetus* from another cat in the household that may or may not be showing clinical signs of infection. It is a common misconception in multiple-cat settings that only cats with diarrhea are infected with *T. foetus*. In these situations, cats undergoing treatment should be isolated from all other cats during and after treatment, and the other cats in the household/cattery should also be tested for *T. foetus*.

Other therapies for the treatment of *T. foetus* infection in cats are limited. Many approaches to control diarrhea have been tried without success, including changes in diet, use of different antibiotics, and supplementation with nutraceuticals and probiotics. However, there have been no controlled studies of any of these therapies. It has been suggested that frequent changes in diet and indiscriminate use of antibiotics prolong the time it takes for cats to resolve the diarrhea on their own. Veterinarians should be cautious to embrace the success of other antimicrobial drugs for treatment of *T. foetus* infection because many drugs merely suppress detection of the organisms rather than eradicate them.

If the owners elect not to treat for *T. foetus* infection, the diarrhea will eventually spontaneously resolve in most cats (88%); however, this can take as long as 2 years.<sup>10</sup> Unfortunately, 55% of these cats remain positive for *T. foetus* infection on PCR testing and therefore may be sources of infection for other cats.<sup>10</sup> Owners of single cats may find this outcome satisfactory

### QuickNotes

The polymerase chain reaction assay is the most sensitive test for diagnosis of *T. foetus* infection in cats.

if the cat remains healthy in other respects. However, in a cattery environment, asymptomatic carriers may perpetuate the infection. The potential health consequences of prolonged asymptomatic infection with *T. foetus* are unknown.

### Conclusion

*T. foetus* is a frequently encountered pathogen that results in chronic waxing and waning large bowel diarrhea. Despite the high prevalence of this parasite in susceptible populations

such as catteries and shelters, testing is still not routine in most veterinary clinics. Specific tests for *T. foetus* infection are readily available and include direct fecal smear, culture of the feces in InPouch TF media, and detection of *T. foetus* in DNA extracted from feces using PCR testing. Ronidazole has effectively treated the infection, although adverse effects such as neurotoxicosis remain problematic in some cases. Untreated cats have spontaneous resolution of diarrhea over time but may remain persistently infected. **C**

REFERENCES ON PAGE 390

3 CE  
CREDITS

**CE TEST 1** This article qualifies for 3 contact hours of continuing education credit from the Auburn University College of Veterinary Medicine. Subscribers may take individual CE tests online and get real-time scores at **CompendiumVet.com**. Those who wish to apply this credit to fulfill state relicensure requirements should consult their respective state authorities regarding the applicability of this program.

1. Which statement regarding feline trichomoniasis is true?
  - a. All infected cats have large bowel diarrhea as a common clinical sign.
  - b. Only young, purebred cats are at risk for infection.
  - c. Cats should self-resolve infection and never require treatment.
  - d. Asymptomatic cats may still represent a source of infection for other cats.
2. \_\_\_\_\_ is/are an effective treatment for cats infected with *T. foetus*.
  - a. Ronidazole
  - b. Metronidazole
  - c. Tinidazole
  - d. Probiotics
3. False-negative PCR results for *T. foetus* can occur if
  - a. old, dried out, nondiarrheic, or litter-contaminated feces are used for testing.
  - b. the cat is currently receiving or has recently (within past 7 days) received antibiotics.
  - c. an insufficient quantity of sample is submitted.
  - d. all of the above
4. Which is a possible explanation if a cat tests positive for *T. foetus* after ronidazole treatment?
  - a. The cat was given ronidazole at <30 mg/kg PO q24h for 14 days.
  - b. The cat was reinfected by another cat in the household.
  - c. An impotent ronidazole formulation was prescribed.
  - d. all of the above
5. Ronidazole can cause \_\_\_\_\_ even at appropriate doses.
  - a. neurotoxicosis (e.g., ataxia, seizures, death)
  - b. immune-mediated hemolytic anemia
  - c. myasthenia gravis
  - d. all of the above
6. The most sensitive test for diagnosing feline trichomoniasis is
  - a. PCR.
  - b. fecal culture.
  - c. fecal smear.
  - d. fecal flotation.
7. The risk of neurotoxicosis associated with ronidazole therapy can be minimized by
  - a. exceeding the recommended dose of 30 mg/kg q24h only in severe cases of infection.
  - b. reducing the dose if signs of neurotoxicosis are observed.
  - c. delaying ronidazole therapy for 7 days if neurotoxicosis develops.
  - d. calculating the dose based on a current, accurate body weight.
8. The index of suspicion for *T. foetus* infection should be high if
  - a. a young shelter cat has waxing and waning, malodorous, large bowel diarrhea.
  - b. trophozoites are observed in a fecal sample, but the infection fails to respond to appropriate doses of metronidazole.
  - c. a young cat has large bowel diarrhea but retains a normal appetite and body condition.
  - d. all of the above
9. \_\_\_\_\_ can be used to diagnose feline trichomoniasis.
  - a. Negative *Giardia* ELISA results
  - b. A fecal float
  - c. A direct fecal smear (wet mount)
  - d. A Baermann test
10. Which statement regarding testing for feline trichomoniasis is true?
  - a. The *T. foetus* PCR test can detect living and dead organisms.
  - b. Nondiarrheic stool samples are preferred for testing.
  - c. *T. foetus* fecal culture detects living and dead organisms.
  - d. The *Giardia* ELISA cross-reacts with *T. foetus*.

## CONTINUED FROM PAGE 381

## References

1. Gookin JL, Breitschwerdt EB, Levy MG, et al. Diarrhea associated with trichomonosis in cats. *JAVMA* 1999;215:1450-1454.
2. Gookin JL, Levy MG, Law JM, et al. Experimental infection of cats with *Tritrichomonas foetus*. *Am J Vet Res* 2001;62:1690-1697.
3. Levy MG, Gookin JL, Poore M, et al. *Tritrichomonas foetus* and not *Pentatrichomonas hominis* is the etiologic agent of feline trichomonal diarrhea. *J Parasitol* 2003;89:99-104.
4. Gookin JL, Stebbins ME, Hunt E, et al. Prevalence of and risk factors for feline *Tritrichomonas foetus* and *Giardia* infection. *J Clin Microbiol* 2004;42:2707-2710.
5. Gunn-Moore DA, McCann TM, Reed N, et al. Prevalence of *Tritrichomonas foetus* infection in cats with diarrhoea in the UK. *J Feline Med Surg* 2007;9:214-218.
6. Steiner JM, Xenoulis PG, Read SA, et al. Identification of *Tritrichomonas foetus* DNA in feces from cats with diarrhea from Germany and Australia. *J Vet Intern Med* 2007;21:649.
7. Bissett SA, Gowan RA, O'Brien CR, et al. Feline diarrhoea associated with *Tritrichomonas cf. foetus* and *Giardia* co-infection in an Australian cattery. *Aust Vet J* 2008;86:440-443.
8. Foster DM, Gookin JL, Poore MF, et al. Outcome of cats with diarrhea and *Tritrichomonas foetus* infection. *JAVMA* 2004;225:888-892.
9. Holliday M, Deni D, Moore D. *Tritrichomonas foetus* infection in cats with diarrhoea in a rescue colony in Italy. *J Feline Med Surg* 2009;11(2):131-134.
10. Gray SG, Hunter S, Stone M, et al. Assessment of reproductive tract disease in cats at risk for enteric *Tritrichomonas foetus* infection. *Am J Vet Res* 2009. In press.
11. Gookin JL, Foster DM, Poore MF, et al. Use of a commercially available culture system for diagnosis of *Tritrichomonas foetus* infection in cats. *JAVMA* 2003;222:1376-1379.
12. Gookin JL, Birkenheuer AJ, Breitschwerdt EB, et al. Single-tube nested PCR for detection of *Tritrichomonas foetus* in feline feces. *J Clin Microbiol* 2002;40:4126-4130.
13. Stauffer SH, Birkenheuer AJ, Levy MG, et al. Evaluation of four DNA extraction methods for the detection of *Tritrichomonas foetus* in feline stool specimens by polymerase chain reaction. *J Vet Diagn Invest* 2008;20:639-641.
14. Kather EJ, Marks SL, Kass PH. Determination of the in vitro susceptibility of feline *Tritrichomonas foetus* to 5 antimicrobial agents. *J Vet Intern Med* 2007;21:966-970.
15. Gookin JL, Copple CN, Papich MG, et al. Efficacy of ronidazole for treatment of feline *Tritrichomonas foetus* infection. *J Vet Intern Med* 2006;20:536-543.
16. LeVine DN, Papich MG, Gookin JL, et al. Ronidazole pharmacokinetics in cats after IV administration and oral administration of an immediate release capsule and a colon-targeted extended release tablet. *J Vet Intern Med* 2008;22:745.
17. Rosado TW, Specht A, Marks SL. Neurotoxicosis in 4 cats receiving ronidazole. *J Vet Intern Med* 2007;21:328-331.
18. Stockdale HD, Givens MD, Dykstra CC, et al. *Tritrichomonas foetus* infections in surveyed pet cats. *Vet Parasitol* 2009;160:13-17.